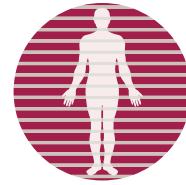


# CT Angiography of the Head and Neck



**SKG**  
RADIOLOGY



Dr Jay Ives, Radiologist

With current generation CT scanners it is possible to obtain spatial resolution of 0.5mm in each plane and to cover extended anatomic ranges. This results in large volume isotropic datasets that can be analysed and displayed with sophisticated visualisation techniques (Figure 1). The rotation rate and detector array size are important to determine the extent of anatomic coverage during the contrast bolus and to image arteries before venous opacification. A 64 row scanner easily covers from the aortic arch into the head without venous contamination.

Angiograms and quantitative data generated from these machines has enabled replacement of more invasive and expensive diagnostic catheter angiography for many body areas including the aorta, limb, renal, visceral, carotid, intracranial, and (for some applications) coronary arteries.

Neurovascular applications include stenotic/occlusive diseases, cerebral aneurysms, vascular malformations, dural sinus thrombosis and fistula, trauma, and mapping for surgical therapy. In this article, the value of CT angiography (CTA) for two common clinical problems is discussed.

## Extracranial Carotid Artery Disease

The severity of arterial narrowing is of major significance and is especially useful in choosing patients for treatment. The studies that established this used diameter stenosis based on angiographic projection imaging. CTA demonstrates the lumen cross-section, allowing direct measurement of lumen dimensions, including area (Figure 2).

Since most stenoses are irregular, diameter measurement is not as haemodynamically valid as area measurement for determining the significance of a stenosis. However, the narrowest diameter is a good predictor of the area, and has been validated against diameter ratio, potentially allowing us to dispense with ratios altogether and describe the actual residual lumen size.

CTA has been shown to underestimate the degree of severe and moderate stenosis compared with Digital Subtraction Angiography. Where calcified plaque is present however, stenosis may be overestimated with CTA.

Current practice stresses the degree of stenosis however this is not the only factor of significance with respect to stroke risk. Other features of atheromatous plaque that have been assessed include expansive vessel wall remodelling, wall thickness, plaque composition, and surface ulceration.

Atherosclerotic arterial remodelling has been described in the coronary circulation, and may also indicate plaque vulnerability in the carotid arteries. A remodelling ratio has been described that is significantly greater in symptomatic than asymptomatic patients, whereas the plaque thickness and eccentricity were not.

Common carotid wall thickness of  $\geq 1$ mm may indicate an increased stroke risk (odds ratio 8.16).

Quantification of plaque composition with CT density can separate stable from unstable plaques in coronary and carotid arteries. Calcium

volume correlates with degree of stenosis, however a greater amount of calcium is found in asymptomatic than symptomatic plaques with stenosis  $> 60\%$ . The distribution of calcification is also important – surface calcification is more common in asymptomatic plaques. Non-calcified plaques or plaques with deep calcification are 12 times more likely to be symptomatic. A detailed comparison of plaque histology with CTA appearances showed good correlation for large lipid cores, haemorrhages, fibrous cap thickness, and ulceration, and perfect concordance for calcification.

CTA has been shown to be superior to ultrasound in the detection of plaque ulceration and to have a high sensitivity and specificity compared to surgical findings.

## Intracranial Arterial Aneurysm

Approximately 2-3% of the population has an unruptured intracranial aneurysm. The major contributors to rupture risk are aneurysm size, history of previous subarachnoid haemorrhage (SAH) from another aneurysm, and to a lesser degree a family history of SAH. Posterior circulation aneurysms carry a higher risk of rupture (0.5% per year) than those in the anterior circulation (0% per year) for aneurysms  $< 7$ mm in size.

Therefore, clinically significant aneurysms should be easily detected by non-invasive techniques such as CTA, which has a reported accuracy of up to 100% for aneurysms of 4mm diameter or greater (Figure 3). Smaller aneurysms are probably more reliably detected by 64 row scanners than with detector arrays of 4 or 16 rows, but when the size is below 3mm even 64 row scanners have low sensitivity.

Unfortunately, when the benefits, risks and cost of treatment are analysed, screening has not proved reasonable in asymptomatic subjects, and benefits only those with previous subarachnoid haemorrhage who are at significant increased risk.

In addition to detection, CTA has been shown to be sufficient to guide endovascular treatment and surgery, and is useful in the detection of vasospasm following subarachnoid haemorrhage. CTA has shown limited ability to accurately detect aneurysms at some anatomic sites (for example the posterior communicating artery), in part due to spatial resolution, and in other cases due to proximity to bone at the skull base. Techniques to subtract bone have shown promise in the latter case.

References available on request

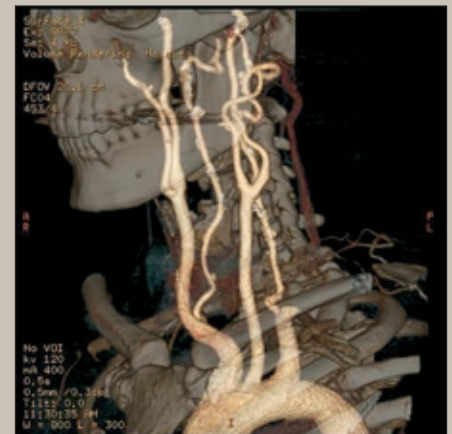

Figure 1

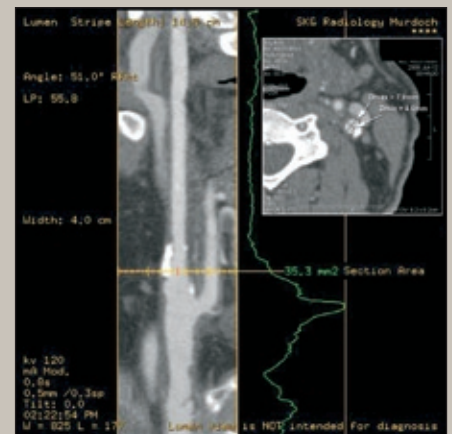


Figure 2

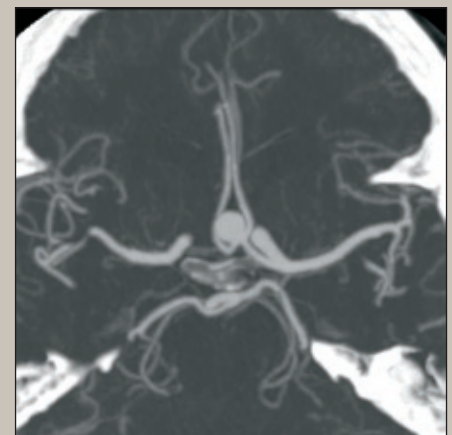


Figure 3