

Imaging of Groin & Abdominal Wall Hernias



By Dr Irvine Tidbury,
Radiologist



Ultrasound (US) in experienced hands is currently the imaging modality of choice for all groin hernias and for most abdominal wall hernias. Postoperative complications, including collections and recurrence, may also be evaluated. US allows unique dynamic evaluation. Patients are usually examined in the supine and erect positions, with and without straining. Computerised Tomography (CT) also has a place, particularly with large complex abdominal wall hernias in the obese patient. These hernias often contain loops of air-filled bowel which preclude adequate penetration of the sound beam by US.

GROIN

Inguinal Hernias

- Most common
- Indirect and direct varieties

Clinically obvious hernias do not usually need ultrasound confirmation. Many surgeons now request ultrasound for confirmation or exclusion of questionable hernias but, more importantly, for evaluation of the asymptomatic side to detect clinically occult hernias. If positive, this allows bilateral hernia repair at a single operation.

Femoral Hernias (Fig 1)

- Not uncommon
- May present with a mass (fluid or fat or a combination)
- May present with a mass (bowel) and obstruction

Obturator Hernias

- Uncommon

ABDOMINAL WALL

Spigelian Hernias (Fig 2)

- Not uncommon
- May occur in combination with inguinal hernias
- Occur at the junction of rectus abdominis and the more lateral anterior abdominal wall muscles

Incisional Hernias

- Postoperative
- May be complex/large requiring CT for optimal evaluation
- May include lumbar and subcostal hernias

Ventral Hernias

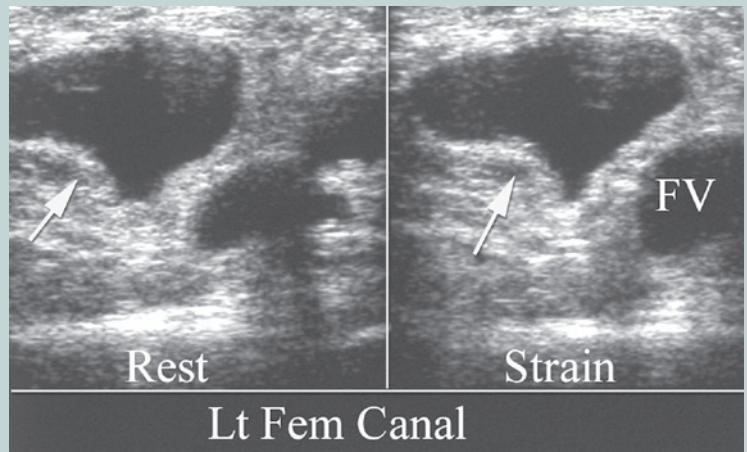
- Defects in the linea alba
- Includes epigastric, supra and infra-umbilical hernias

Umbilical Hernias

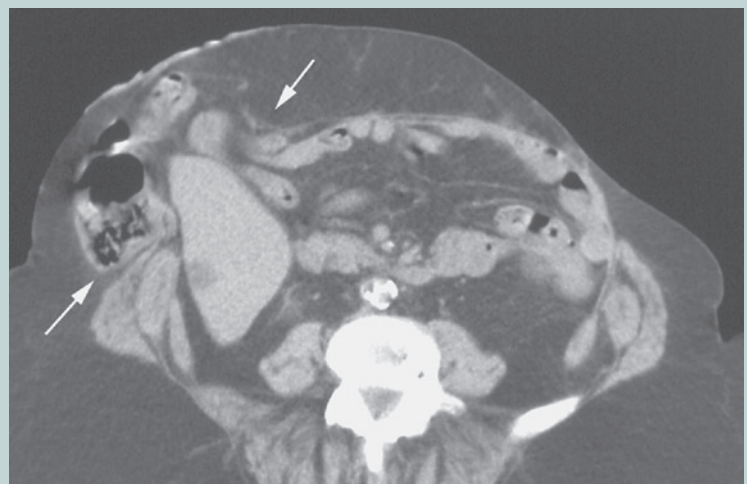- Common and often clinically obvious
- Confirmed with US

CONDITIONS THAT MAY MIMIC HERNIAS (Fig 3)

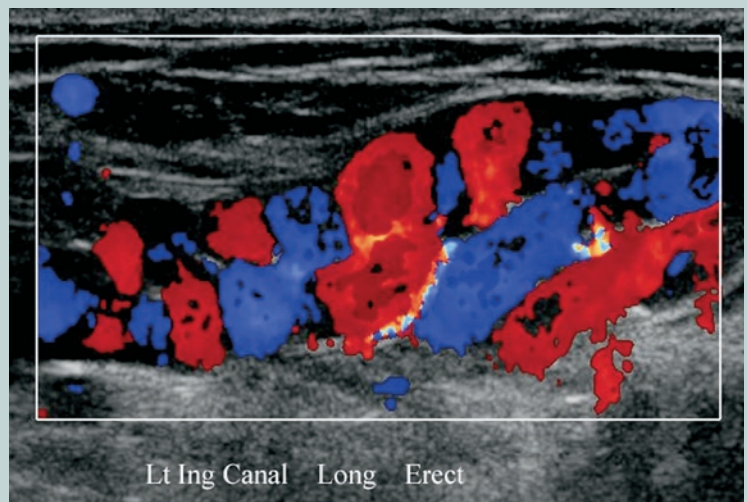
- Divarication of the recti
- Encysted hydrocele of the cord
- Cord lipoma
- Varices of the round ligament (typically 3rd trimester)



■ Fig 1. US shows a left femoral hernia containing fluid medial to the femoral vein.



■ Fig 2. CT demonstration of complex Spigelian hernia containing small and large bowel, fat and liver.



■ Fig 3. US colour doppler image of round ligament varices in a 3rd trimester pregnancy. The groin mass in the inguinal canal may present clinically as a hernia.